

Cranial in the Osteopathic Field... Clinical Application

Kelli Buckner, DO


CAOM Jan 26, 2020




Objectives

- Consider common conditions that respond well to Cranial Treatment
- Introduce basic concepts of Osteopathy in the Cranial Field
- Practice some Cranial Techniques

So what can it be used for?

- 
- Since all membranous structures in the body are composed of connective tissue derived from embryonic mesenchyme, all membranes are therefore continuous with other mesenchymally derived tissues throughout the body.
 - **As a result, the intracranial membranes are intimately related to the fascia of the rest of the body...**

- 
- Pleigiocephaly
 - Strabismus
 - Torticollis
 - Concussion/Traumatic Brain Injury
 - Migraine HA
 - Tinnitus
 - Vertigo
 - ...

- Otitis Media
- Eustacian Tube Dysfunction
- Sinusitis-Acute and Chronic
- TMJ Disorder
- Feeding disorders in infants
- Digestive problems
- Scoliosis
- ...

Pleigiocephaly



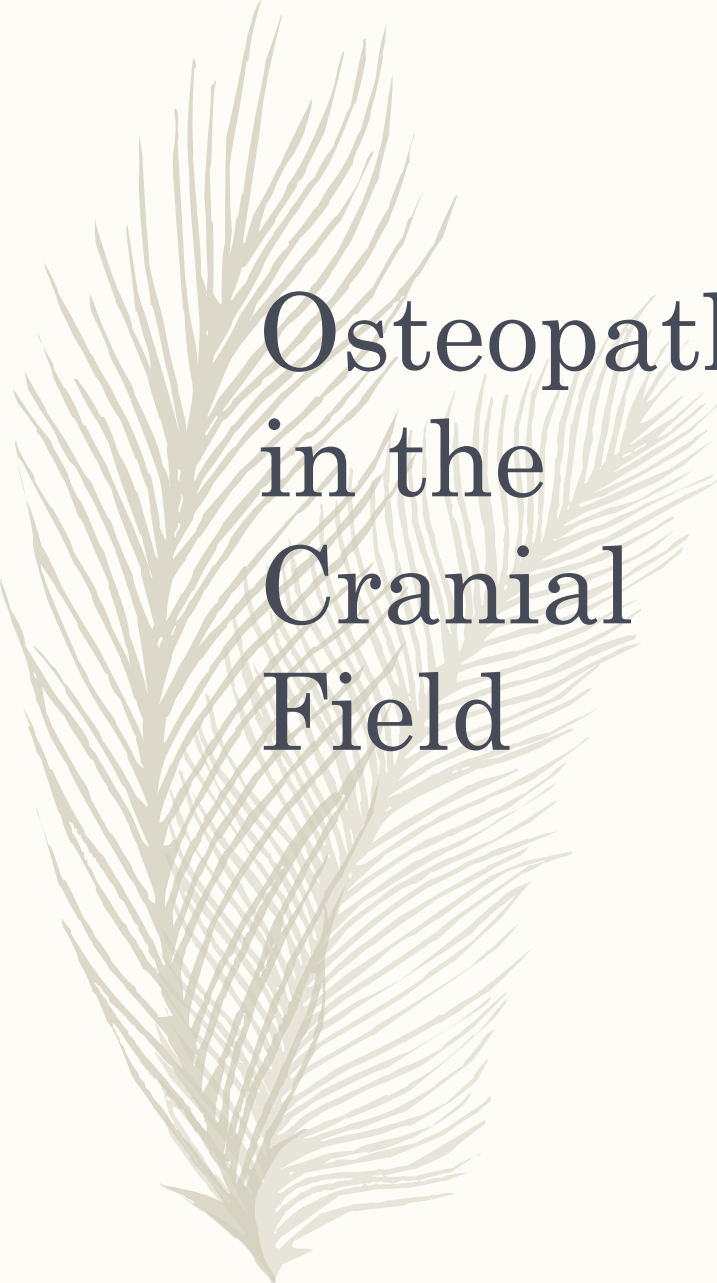
Scoliosis

A decorative illustration of a pine branch with many fine needles, rendered in a light green color, positioned on the left side of the slide.

2 mos of OCF
treatment

C. S.

- A 4 week old male presents for symptoms of Nursing Difficulties and GERD. He arches with feeding, pulls off frequently, has difficulty nursing on the R, spits up copious amounts, cries, screams and is stiff during and after nursing. He also tends to hold his head more to the left.
- He has been taking Nexium for 1 week, some symptoms have improved, but he is still relatively uncomfortable during and after feeding and struggles to nurse the right.
- Treatment once monthly, after second treatment his Nexium was decreased by ½, then discontinued 2 weeks later.
- After 3 treatments, he nurses normally on both sides, does not cry, scream, arch, pull off or spit up during or after nursing.



Osteopathy in the Cranial Field

- Cranial osteopathy is the study of the anatomy and physiology of the cranium, the central nervous system, and the cerebrospinal fluid, and their inter-relationship with the body as a whole. It may be applied for the prevention and treatment of disease and enhancement of health, within the practice of the science of osteopathy.
 - *As defined by the Osteopathic Cranial Academy*




Primary Respiratory Mechanism: 5 Principles

- Fluctuation of the CSF and the potency of the tide
- Mobility of the intracranial and intraspinal membranes and the function of the RTM
- Inherent motility of CNS
- Articular mobility of the Cranial bones
- Involuntary motion of the sacrum between the ilia via the dural connection at body of S2



Cranial Rhythmic Impulse


- The palpable manifestation of the PRM.
- Basic rate is 8-14 cycles per minute



Enough already!!!

“this application of tactile sense cannot be acquired through observation of the other fellow’s manipulations; nor can it be gained readily from the printed text. It may be best acquired by the student having the hands upon the site of the desired movement...following therewith intelligently with the tactile sense, feeling, seeing, thinking, as the tissue is being guided carefully, gently, firmly, and scientifically, into normal relationship.”

William G Sutherland, *The Cranial Bowl*, 1939, p 67



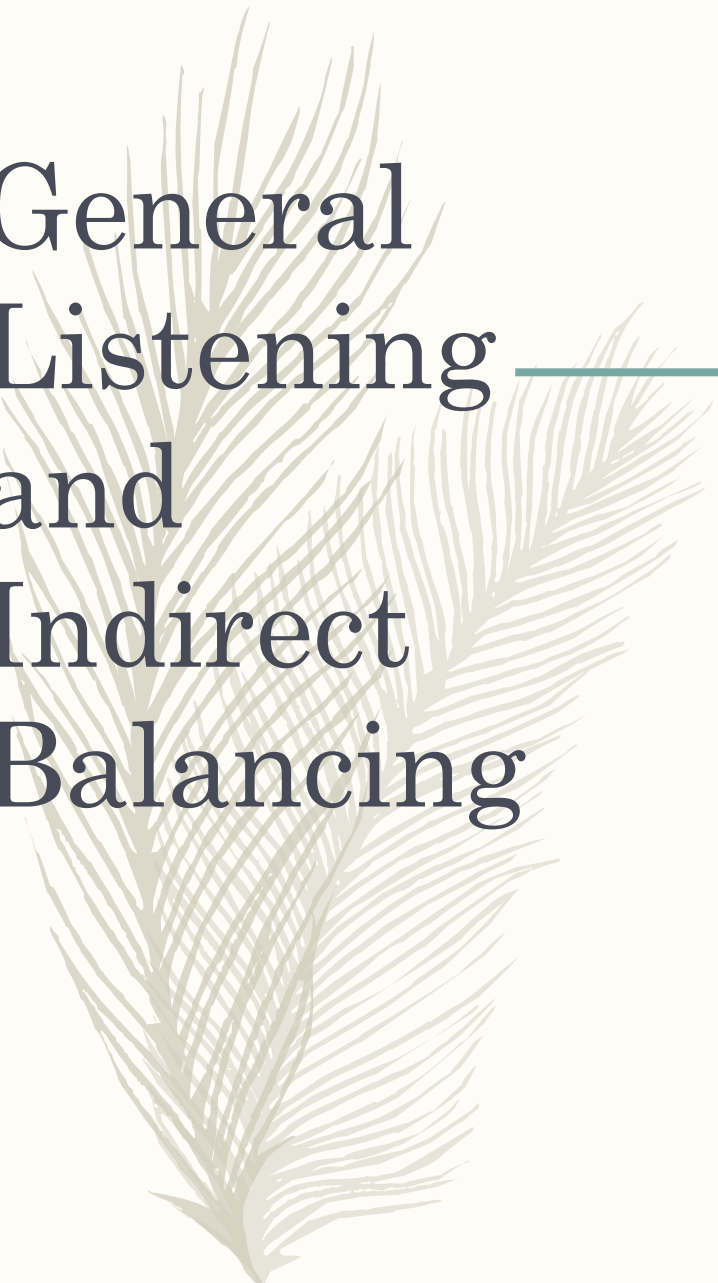
“The force of
gentleness is
great...”

Constantine Hering, MD
-19th Century Homeopath



Palpation

- VAULT
 - Thumbs off the head around vertex
 - Second digit (Index finger) at greater wings of the sphenoid
 - 3rd and 4th digits straddle the ear
 - 5th digit on the occiput
- Fronto-Occipito
 - Lateral cupping of occiput in one hand
 - Lateral spanning of the greater wings of the sphenoid with thumb and 4th digit



General Listening and Indirect Balancing

Ethmoid/Vomer Decompression

- 2 fingers across the glabella near the supraorbital notch
- Thumb and index finger of other hand just below the bridge of the nose
- Gently distract and balance in multiple planes until softening and balance is felt

A large, stylized feather graphic in a light beige color, positioned on the left side of the slide. It has a central rachis with many fine, radiating barbs, giving it a soft, downy appearance.

Ear Pull

Gentle lateral and cephalad or caudad pressure is exerted through the lobes of both ears until freedom of motion is restored



OC Decompression

- Contact occipital condyles
- Apply gentle lateral and cephalad traction until tissue softens and balance is felt

Occipital Condylar Decompression





References

- Osteopathic Cranial Academy.
<http://cranialacademy.org>
- DiGiovanna, E. L., Schiowitz, S. and D.J. Dowling. ***An Osteopathic Approach to Diagnosis and Treatment.*** 3rd Edition. Pp109-112, 549-582.
- Greenman, Philip E. ***Principles of Manual Medicine.*** 3rd Edition. Pp 171-194.
- Balmer, John, DO. Jan 2006, **LECOM**
- Sutherland, W G. ***The Cranial Bowl.*** P 67
- Photos used with permission



Questions?

- Feel free to contact me!
- Kelli Buckner D.O.
- *kbuckner@bowtiemedical.com*