



OMT for  
THAT!!!??

Really???

---

Kelli Buckner, DO

CAOM Jan 28, 2018



# Objectives

---

- Discuss complaints of the head and face that can benefit from the application of OMT techniques
- Introduce basic concepts of Osteopathy in the Cranial Field
- Practice some Cranial Techniques

# Case 1: G.R.

---

- G. R. is a 58 y/o male who presents with diagnosis of Meniere Disease and symptoms of R ear fullness, Tinnitus, Dizziness and nausea.
- After 3 sessions, he reports that his dizziness has subsided almost completely for the first time since his diagnosis 1 ½ years prior
- Monthly maintenance treatments
- After 5 months, he went on a skiing trip for the first time since his diagnosis and was asymptomatic. 6 months into treatment he had resumed all of his former activities including hiking, sailboat racing and waterskiing. Dizziness occurs only intermittently, feeling of fullness is gone, nausea is gone, tinnitus persists, although less severe.



## Case 2: T. S.

---

- T. S. is a 50 y/o female who presents 1 week after finishing antibiotic treatment for sinusitis. She complains now that the R side of her nose is blocked. She is unable to sleep due to the blockage and is very uncomfortable. She denies any drainage or recurrence of the symptoms of her sinusitis.
- She has been using Flonase for 4 days with no change in her symptoms.
- On exam she has an enlarged, non-obstructing nasal turbinate with pale mucosa noted.
- She was treated and at her follow up visit 1 week later she exclaimed “I am 100% better!” Within 2 days of her treatment she was able to sleep all night and was relatively asymptomatic.



# Case 3: C. S.

---

- C. S. is a 4 week old male who presents for symptoms of Colic and GERD. He arches with feeding, pulls off frequently, has difficulty nursing on the R, spits up copious amounts, cries, screams and is stiff during and after nursing. He also tends to hold his head more to the left.
- He has been taking Nexium for 1 week, some symptoms have improved, but he is still relatively uncomfortable during and after feeding.
- Treatment once monthly, after second treatment his Nexium was decreased by ½, then discontinued 2 weeks later.
- After 3 treatments, he nurses normally on both sides, does not cry, scream, arch, pull off or spit up during or after nursing.





## Case 4: S. K.

- S. K. is a 30 y/o female. She presents because she is trying to become scuba certified, but she cannot descend to the proper depth due to ear pain and pressure. She denies any other symptoms or concerns.
- She was treated 3 times, 1 week apart. She then completed her scuba testing without incident and received her certification.

# Case 5: L. H.

---

- L. H. presents for the first time at 5 months of age as a referral from her pediatrician for cranial asymmetry and neck tightness. She was found to have significant pleigiocephaly and torticollis. Mother reports that this has been progressing since birth despite regular treatment by their chiropractor.
- Pediatrician discussed helmet treatment for the asymmetry as well, but parents declined.







- On her first follow up visit, 2 weeks later, mom reports that after the first treatment she sat up for the first time without falling to the left.
- She was treated again at that time. She was unable to follow up again for 5 months.
- She presented again for treatment at age 10 months, was treated once per month for 4 sessions...

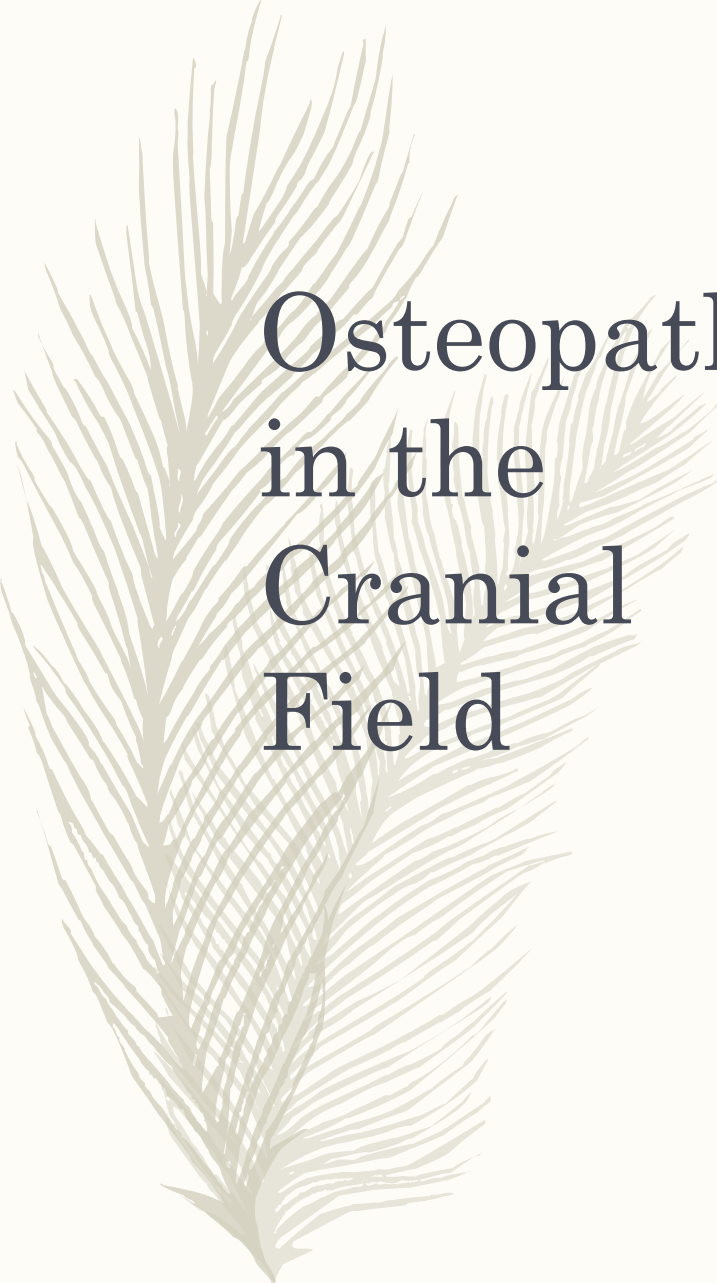




# And oh so many others!

---

- Strabismus
- Torticollis
- Concussion/Traumatic Brain Injury
- Migraine HA
- Tinnitus
- Otitis Media
- Sinusitis-Acute and Chronic
- TMJ Disorder
- Vertigo



# Osteopathy in the Cranial Field

- Cranial osteopathy is the study of the anatomy and physiology of the cranium, the central nervous system, and the cerebrospinal fluid, and their inter-relationship with the body as a whole. It may be applied for the prevention and treatment of disease and enhancement of health, within the practice of the science of osteopathy.
  - *As defined by the Osteopathic Cranial Academy*



# Primary Respiratory Mechanism: 5 Principles

- Fluctuation of the CSF and the potency of the tide
- Mobility of the intracranial and intraspinal membranes and the function of the RTM
- Inherent motility of CNS
- Articular mobility of the Cranial bones
- Involuntary motion of the sacrum between the ilia via the dural connection at body of S2




# Cranial Rhythmic Impulse

---

- The palpable manifestation of the PRM.
- Basic rate is 8-14 cycles per minute





# Enough already!!!


“this application of tactile sense cannot be acquired through observation of the other fellow’s manipulations; nor can it be gained readily from the printed text. It may be best acquired by the student having the hands upon the site of the desired movement...following therewith intelligently with the tactile sense, feeling, seeing, thinking, as the tissue is being guided carefully, gently, firmly, and scientifically, into normal relationship.”

William G Sutherland, *The Cranial Bowl*, 1939, p 67



# Palpation

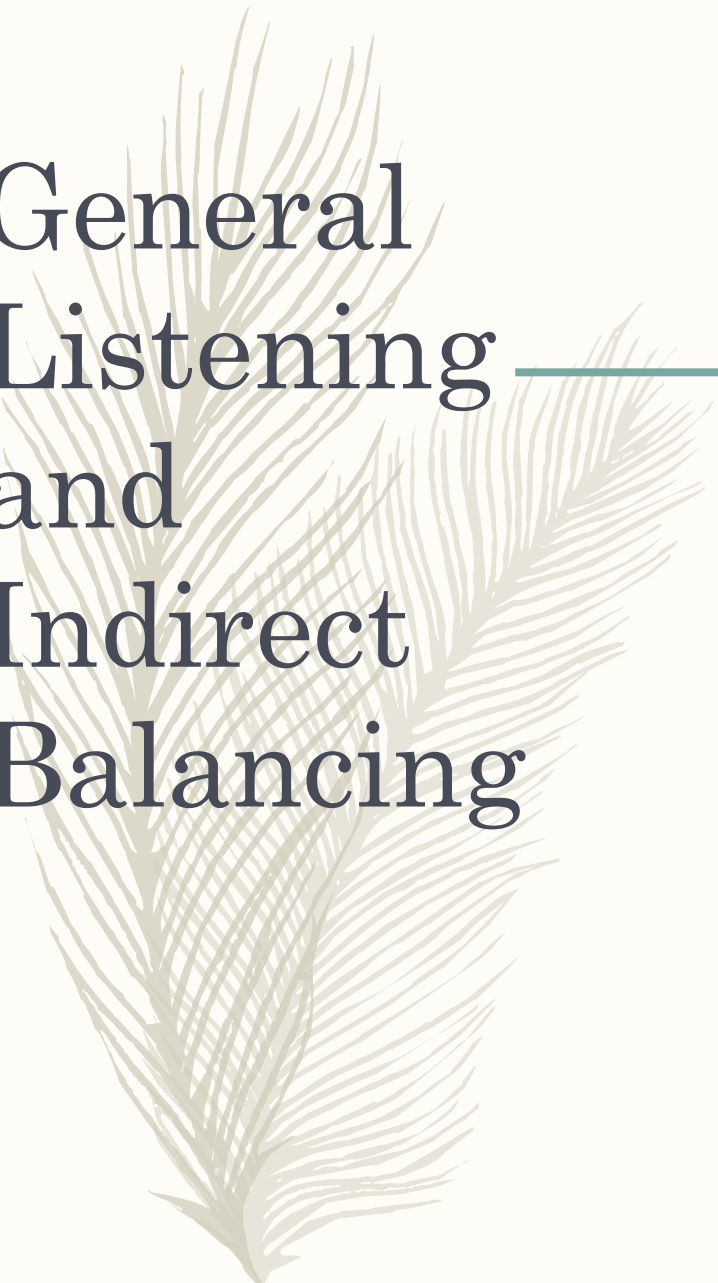
- VAULT
  - Thumbs off the head around vertex
  - Second digit (Index finger) at greater wings of the sphenoid
  - 3<sup>rd</sup> and 4<sup>th</sup> digits straddle the ear
  - 5<sup>th</sup> digit on the occiput
- Fronto-Occipito
  - Lateral cupping of occiput in one hand
  - Lateral spanning of the greater wings of the sphenoid with thumb and 4<sup>th</sup> digit



“The force of  
gentleness is  
great...”

---

Constantine Hering, MD  
-19th Century Homeopath



# General Listening and Indirect Balancing

---

# Ethmoid/Vomer Decompression

---

- 2 fingers across the glabella near the supraorbital notch
- Thumb and index finger of other hand just below the bridge of the nose
- Gently distract and balance in multiple planes until softening and balance is felt



## Ear Pull

Gentle lateral and cephalad or caudad pressure is exerted through the lobes of both ears until freedom of motion is restored

---



# OC Decompression

- Contact occipital condyles
- Apply gentle lateral and cephalad traction until tissue softens and balance is felt



# Occipital Condylar Decompression

---





# References

- Osteopathic Cranial Academy.  
<http://cranialacademy.org>
- DiGiovanna, E. L., Schiowitz, S. and D.J. Dowling. ***An Osteopathic Approach to Diagnosis and Treatment.*** 3<sup>rd</sup> Edition. Pp109-112, 549-582.
- Greenman, Philip E. ***Principles of Manual Medicine.*** 3<sup>rd</sup> Edition. Pp 171-194.
- Balmer, John, DO. Jan 2006, **LECOM**
- Sutherland, W G. ***The Cranial Bowl.*** P 67



# Thanks!

---

- Feel free to contact me!
- Kelli Buckner D.O.
- *[kbuckner@bowtiemedical.com](mailto:kbuckner@bowtiemedical.com)*